Maxillary Distobuccal Vestibule Assessment

Pre-treatment evaluation for mandibular advancement splints

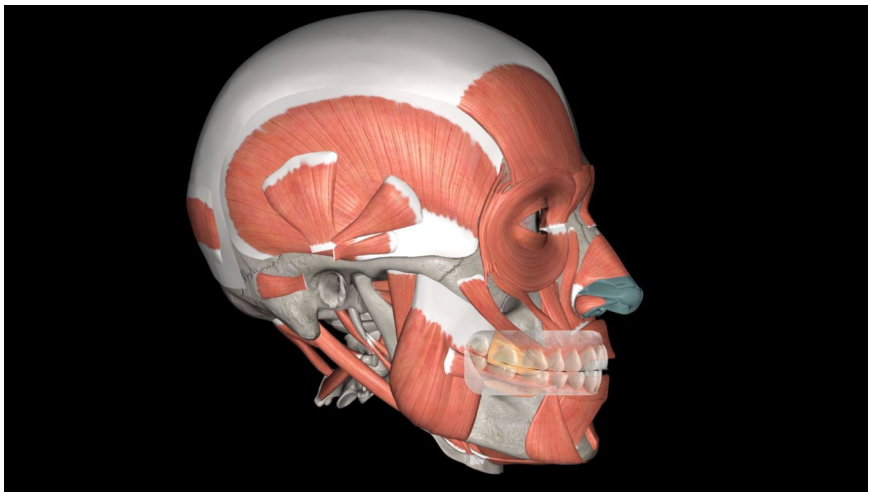

Figure: Lateral anatomical view to demonstrate the relationship between musculature, maxillary dentition, and the maxillary distobuccal vestibule (adjacent to the upper first and second molars).

Purpose of the assessment

When planning a mandibular advancement splint (MAS), it is essential to determine how much functional buccal space is available in the maxillary distobuccal vestibule during mandibular closure.

Clinical assessment technique

1. Retract the cheek and place the index finger into the maxillary buccal sulcus.
2. Slide posteriorly from the canine past the premolars to the region adjacent to the upper first and second molars.
3. Ask the patient to gently close their teeth together (light clench only).
4. Observe the tissue response and stop closure at the first sensation of pressure or discomfort.

Interpretation

Expanding vestibule – tissue moves away from the finger on closure.

Neutral vestibule – minimal change in tissue position.

Contracting vestibule – tissue compresses or pinches against the finger.

MAS design implications

Expanding: greater tolerance for posterior bulk and standard fin position.

Neutral: conventional fin position.

Contracting: more anterior placed fins, or alternate design for MAS (not Aer Dorsal)